

© Group of authors, 2016
UDC 616.3-089-089.843-092.9
DOI – <http://dx.doi.org/10.14300/mnnc.2016.11036>
ISSN – 2073-8137

ESOPHAGUS DECELLULARIZATION PROTOCOLS IN MACACA MULATTA MODEL

Sotnichenko A. S.¹, Gubareva E. A.¹, Kuevda E. V.¹, Gumenyuk I. S.¹, Gilevich I. V.¹,
Orlov S. V.², Macchiarini P.^{1,3}

¹ Kuban State Medical University, Krasnodar, Russian Federation

² Research Institute of Medical Primatology, Sochi, Adler, Russian Federation

³ Karolinska Institute, Advanced Center of translational regenerative medicine,
Stockholm, Sweden

СРАВНИТЕЛЬНЫЙ АНАЛИЗ ПРОТОКОЛОВ ДЕЦЕЛЛЮЛЯРИЗАЦИИ ПИЩЕВОДА НА МОДЕЛИ МАСАСА MULATTA

А. С. Сотниченко¹, Е. А. Губарева¹, Е. В. Куевда¹, И. С. Гуменюк¹, И. В. Гилевич¹,
С. В. Орлов², П. Маккиарини³

¹ Кубанский государственный медицинский университет, Краснодар,
Российская Федерация

² Научно-исследовательский институт медицинской приматологии, Сочи,
Адлер, Российская Федерация

³ Каролинский институт, Ведущий центр трансляционной регенеративной
медицины, Стокгольм, Швеция

Decellularization is used in biomedical engineering to isolate the extracellular matrix (ECM) from its inhabiting cells, preserving the ECM of the scaffold, which could be used for biological non-immunogenic and non-toxic scaffolds obtainment for creation of full-fledged organs and tissues. Taking into account the importance of transferring results into clinic, the model of the non-human primates is the most suitable model for carrying out preclinical research. We have developed two protocols of *Macaca mulatta* esophagus decellularization by the modified detergent and enzymatic method differing in samples storage conditions, preparation for decellularization process, and also composition and duration of decellularizing agents' exposure. The obtained scaffolds maintain anatomical and morphological properties of a native esophagus as well as components of an ECM. The DNA-quantity substantially decreases when using detergents and enzymes. At the same time it is shown that organs' freezing at $-30\text{ }^{\circ}\text{C}$ requires protocol modification for lengthening of transportation and storage time and the subsequent thawing for decellularization.

Key words: decellularization, esophagus, extracellular matrix, Macaca mulatta

Для получения биологических каркасов, лишенных иммуногенных и токсических свойств, лежащих в основе создания полноценных тканеинженерных конструкций органов и тканей, перспективным методом является децеллюляризация. С учетом важности будущего трансфера результатов в клинику наиболее подходящей моделью для проведения доклинических исследований является модель низших приматов. Нами разработано два протокола проведения децеллюляризации пищевода *Macaca mulatta* модифицированным детергентно-энзиматическим методом, отличающихся условиями хранения образцов, подготовкой к проведению процесса децеллюляризации, а также составом и продолжительностью воздействия децеллюляризирующих агентов. Полученные каркасы сохраняют анатомо-морфологические свойства нативного пищевода и основные компоненты внеклеточного матрикса. Количественное содержание ДНК в значительной степени снижается при использовании детергентов и энзимов. При этом показано, что заморозка органов в морозильной камере при $-30\text{ }^{\circ}\text{C}$ для удлинения времени транспортировки и хранения и последующее их оттаивание в целях децеллюляризации требует внесения изменений в протокол проведения данной процедуры.

Ключевые слова: децеллюляризация, пищевод, внеклеточный матрикс, Macaca mulatta

Tissue engineering is one of the branches of regenerative medicine that may offer an alternative treatment option for patients in need of organ transplantation. The main point of tissue engineering is restoring structural and functional

intactness of tissues and organs using bioartificial constructions, which include the following [3]:

- Cells able to create functioning extracellular matrix.
- Suitable biodegradable scaffold (matrix) for cells transplantation.

– Bioactive molecules (cytokines, growth factors) stimulating cells of damaged tissues.

The priority area of modern tissue engineering is search for bioengineered scaffolds and biomaterials which use would help to solve ethical and immunological problems of transplantology.

Creation of bioengineered scaffolds requires decellularization of native organs to get non-immunogenic matrices. Decellularization should be aimed at maintenance of biochemical composition, tissue structure and mechanical properties of preserved extracellular matrix at an optimal level [4].

Nowadays there is a problem of explantation and timely delivery of primates' organs for decellularization immediately before the procedure. Important is also the search for optimal way of organ storage, helping to maintain its structure as intact as possible and decrease the risk of possible bacterial contamination and putrefaction.

Objective of the research is comparison of the results of *Macaca mulatta* esophagus decellularization, carried out by the previously described protocol [1], with the results, obtained after a long-term storage of organ at -30°C .

Material and Methods. Organs of 4 male rhesus macaques (*Macaca mulatta*) were used for creation of a decellularized matrix of a tissue engineered esophagus. All manipulations with animals were carried out with observance of rules of work with experimental animals (the protocol of local ethical committee № 30/1). The explantation of organ complexes was carried out in Research institute of medical primatology. Then the esophagus was transported to the laboratory in the cooled PBS solution +/- (Gibco, England) at $+4^{\circ}\text{C}$. Time of delivery was no more than 2 hours. At this stage there was carried out either decellularization (protocol No. 1) or organ freezing at -30°C with its following preservation in the freezer for the delayed performance of a decellularization (protocol № 2).

For decellularization an esophagus of *Macaca mulatta* was unfreezing (protocol № 2) at $+4^{\circ}\text{C}$ during 16 hours, further it was separated (protocol № 1–2) in sterile conditions by means of tweezers and scissors from the connective tissue surrounding it. For decellularization cranial and caudal parts of an esophagus were cannulated with plastic catheters by their diameter. The organ was attached to a peristaltic pump by means of connecting tubes and placed in the specialized ORCA bioreactor (Harvard Apparatus, USA) (Fig. 1).

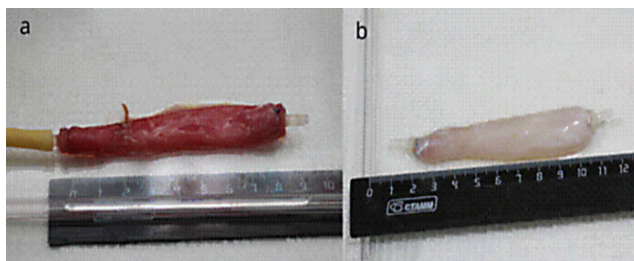


Fig. 1. Native (a) and decellularized (b) esophagus of *Macaca mulatta*

The original protocol of rat esophagus decellularization by detergent-enzymatic method [8] has been modified by us with a change of exposure time, structure and decellularizing solutions perfusion sequence for obtainment of esophagus acellular matrix of *Macaca mulatta* – the protocol № 1 [1, 2]. Other procedure – the protocol № 2 (Table) – has been developed for decellularization of *Macaca mulatta* esophagus stored at a temperature of -30°C .

Table

Algorithm of esophagus decellularization by different protocols

	Protocol № 1	Protocol № 2
Samples' storage conditions	Phosphate buffer solution at $+4^{\circ}\text{C}$	Freezing chamber at -30°C
Sequence of detergents and enzymes (for one cycle)	1. DI water (1 h); 2. Sodium deoxycholate 4 % solution + mM EDTA solution (1 h); 3. PBS +/- (10 min); 4. Porcine pancreatic DNase-I 2000 units of activity /200 ml PBS +/- (1 h)	1. Sodium deoxycholate 4 % solution + 2 mM EDTA solution (1 h); 2. DI water (1h); 3. Porcine pancreatic DNase-I 2000 units of activity / 200 ml PBS +/- (1 h)
Total cycles' amount	2	4
Perfusion rate	150 ml/min	21 ml/min
Total duration	24 h	24 h

The obtained samples of a native and decellularized esophagus fixed in 10 % neutral buffering formalin were dehydrated and embedded in paraffin by a standard technique. With the use of the microtome 5 microns thick sections were obtained. For *general histologic assessment* the samples were stained with hematoxylin and eosin (Histolab, Sweden). For *immunohistochemical analysis* primary polyclonal antibodies to collagen I (ab34710, Abcam, England), to collagen IV (ab6586, Abcam, England), to laminin (ab11575, Abcam, England), to fibronectin (ab2413, Abcam, England), to tropomyosin (ab133292, Abcam, England), to pan-cytokeratin (ab7753, Abcam, England), to VEGF (ab46154, Abcam, England) were chosen.

Samples were additionally stained with hematoxylin. Evaluation of microsections was carried out on a microscope Olympus BX51 (Japan). The evaluation method of the positively stained area of the studied samples in a narrow spectral area with an optical density above the threshold on the basis of the color deconvolution principle has been applied to the quantitative analysis of immunohistochemically stained results [7].

For *DNA quantification* of native and decellularized organs (n=4) the reagent kits (Dneasy Blood and Tissue Kit, Qiagen, Sweden) were used by standard protocols at the NanoDrop ND-1000 spectrophotometer (Thermo Fisher Scientific Inc., USA).

Statistical analysis of obtained data was carried out by variation statistics method on a personal computer using Excel forms Office software. The obtained results were expressed as mid-values (M) and error of mean (m). In mid-values comparison of assessed groups a percent of potential error was looked for in the Student's t-criteria table for pairwise comparison, expressed as values of statistical significance, where $p < 0.05$ was considered statistically significant.

Results and Discussion. When decellularized by the protocol № 1, the esophagus discolored to milky-white, which is characteristic for acellular matrices within 2 operation cycles (6 hours of active detergents and enzymes exposure). Hematoxylin and eosin staining hasn't revealed any signs of cells and nuclei. Histoarchitectonics proper to a native esophagus tissue remained intact. An epithelium (nuclei-free cells), a basal membrane and a submucosa consisting of loose areolar connective tissue were detected. The muscular layer was also acellular; occasional damaged muscle fibers of an external muscular layer free of nuclei remained (Fig. 2).

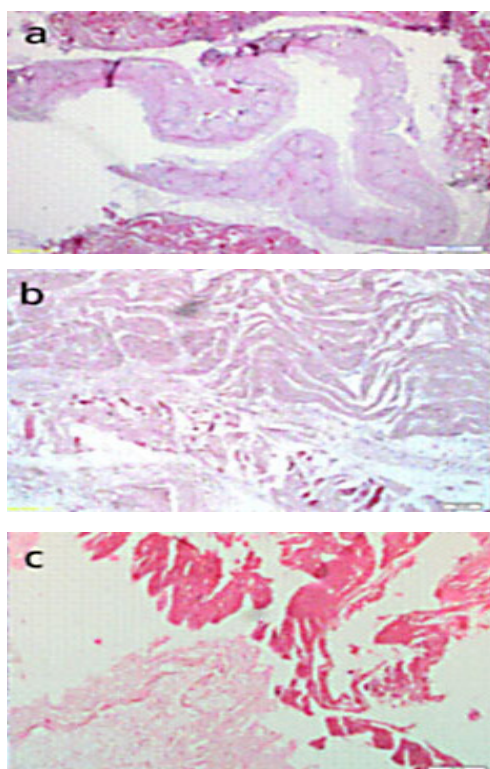


Fig. 2. Morphology of *Macaca's mulatta* esophagi: native (a), decellularized with protocol № 1(b), decellularized with protocol № 2 (c). Hematoxylin and eosin staining. Magnification 100 x

The protocol № 2 had essential distinctions. It should be noted that the cycle of freezing and thawing of an organ itself is one of the stages of acellular matrix obtainment [5]. As a result cells' lysis occurs. However, membrane structures and intracellular contents remain, if they aren't eliminated by the subsequent processing. In this case there is also a damage of extracellular matrix's ultrastructure which can impact its biomechanical characteristics [6]. We have noted that the effective decellularization of esophagus tissues which have undergone freezing and thawing, first, requires larger amount of cycles of detergents and enzymes exposure – 4 instead of 2 that, respectively, increases time of their active exposure (12 hours in comparison to 6 hours when using the protocol № 1). Increase in time of procedure, leads to larger damage of a matrix, and, perhaps, will worsen its further interaction with stem cells at organ's recellularization. Secondly, a distinctive feature of the protocol № 2 was reduction of decellularizing solutions flow rate from 150 ml/min to 21 ml/min that responds to the decrease in mechanical durability of organ after thawing. The intact cells and cells nuclei were absent in an esophagus extracellular matrix of *Macaca mulatta*, obtained by the protocol № 2. At the same time there was more considerable separation of fibers of extracellular matrix structures, which are mainly located in a submucosa. A more prominent expression of tropomyosin, which was removed less effective, was detected in a muscular layer.

Confirmation of safety of extracellular matrix components and lack of intracellular proteins by quantitative methods was especially important. The comparative quantitative analysis of content of the main structural and intracellular proteins has shown, that both protocols of decellularization allow maintaining such proteins as collagen I and IV, laminin and a VEGF in a matrix.

However, at a decellularization by the protocol № 2 the maintenance of a fibronectin in a matrix was significantly lower, that is probably connected with its instability to freezing and thawing. At the same time the content of intracellular contractile protein tropomyosin capable to elicit the immune response, in this case was higher, than at a decellularization by the protocol № 1 (Fig. 3).

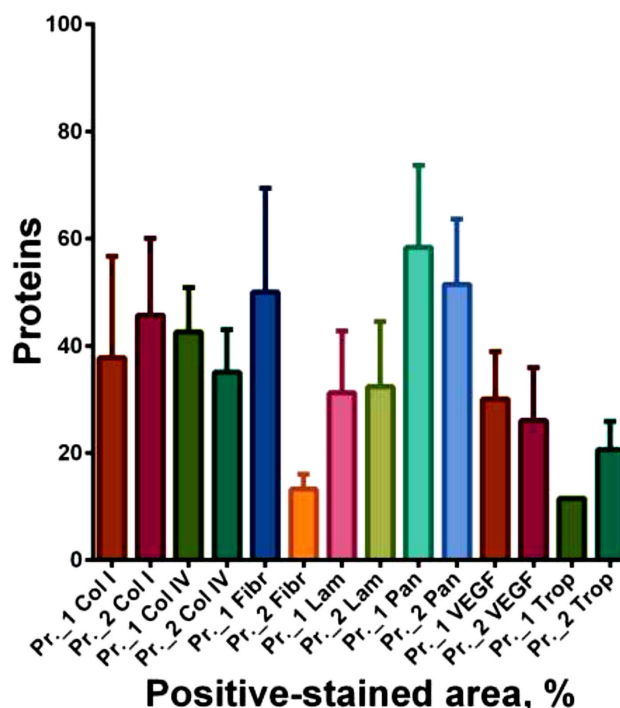


Fig. 3. Quantitative analysis of extracellular proteins in esophagus samples decellularized according to different protocols

The analysis of DNA quantity has shown decrease in amount of nuclear material in a decellularized esophagus by the protocol №1 down to 29 % and by the protocol № 2 down to 36 % of initial level. The obtained results testified to efficiency of the carried out decellularization after which matrix was substantially ($p= 0.0011$) cleared of nuclear material.

Conclusions. Organs freezing at $-30\text{ }^{\circ}\text{C}$ for lengthening of transportation and storage period and the subsequent thawing for decellularization require modification of the protocol of this procedure. First, it is necessary to increase amount of cycles of detergents and enzymes exposure, secondly, it is required to reduce the perfusion rate of matrix for preservation of its mechanical integrity. Content of the main proteins of an extracellular matrix and level of residual DNA in both protocols of decellularization differs not considerably, however damage of structure after freezing and thawing has more expressed character. Thus, it is possible to resort to freezing and storage of *Macaca mulatta* esophagus only in exceptional cases and with obligatory modification of the protocol of decellularization.

Acknowledgements. Research was performed under the support of the governmental task of the Ministry of Healthcare of the Russian Federation «Development of research prototypes of tissue engineered constructions based on decellularized matrices for use in regenerative medicine» and Grant of the Russian Science Foundation № 14-45-00018 «Development of tissue-engineered esophagus for organ replacement in NHP model».

References

1. Gubareva E. A., Sotnichenko A. S., Kuevda E. V. Immunologicheskaya charakteristika decellularizatsii pischevoda nizchego primata. *Sovremennye problemi nauki i obrazovaniya. – Modern problems science and educations.* 2015;2(2):780.
2. Gubareva E. A., Sjöqvist S., Sotnichenko A. S. Decellularizatsiya pischevoda nizchich primatov. *Geni i kletki – Genes & Cells.* 2014;9(4):64-69.
3. Atala A. Tissue engineering, stem cells and cloning: current concepts and changing trends. 2005.
4. Badylak S. F. The extracellular matrix as a biologic scaffold material *Biomaterials.* 2007;28(25):3587-3593.
5. Badylak S. F., Taylor D., Uygun K. Whole-organ tissue engineering: decellularization and recellularization of three-dimensional matrix scaffolds. *Annual review of biomedical engineering.* 2011;13:27-53.
6. Crapo P. M., Gilbert T. W., Badylak S. F. An overview of tissue and whole organ decellularization processes. *Biomaterials.* 2011;32(12):3233-3243.
7. Ruifrok A. C., Johnston D. A. Quantification of histochemical staining by color deconvolution. Analytical and quantitative cytology and histology. *The International Academy of Cytology [and] American Society of Cytology.* 2001;23(4):291-299.
8. Sjöqvist S., Jungebluth P., Lim M. L. Experimental orthotopic transplantation of a tissue-engineered oesophagus in rats. *Nature communications.* 2014;5:3562.

About authors:

Sotnichenko Alexander, research fellow at the laboratory of fundamental research in the field of regenerative medicine, teaching assistant of the pathologic anatomy department; tel.: +7962851-82-37; e-mail: alex24.88@mail.ru

Gubareva Elena, cms, Head of the laboratory of fundamental research in the field of regenerative medicine, docent at the general and clinical pathology department; tel.: +79181327857; e-mail: g_lena82@list.ru

Gilevich Irina, postgraduated student at the department of oncology with a course of thoracic surgery; tel.: +79183227556; e-mail: giliv@list.ru

Orlov Sergey, dms, Director of Research Institute of Medical Primatology; tel.: +79186034838; e-mail: orloff-sv@mail.ru

Macchiarini Paolo, MD, PhD, Megagrant leading scientist, Head of the International research, clinical and educational Center of Regenerative Medicine, Krasnodar; Advanced Center for Translational regenerative Medicine, Karolinska Institute; e-mail: paolo.macchiarini@ki.se

© Group of authors, 2016

UDC 616.735.8.002.61:34.47.002.33.14.009.02

DOI – <http://dx.doi.org/10.14300/mnnc.2016.11037>

ISSN – 2073-8137

PATHOPHYSIOLOGICAL MECHANISMS BEHIND EXPERIMENTAL ODONTOGENIC MAXILLITIS

Koshel I. V., Shchetin E. V., Sirak S. V.

Stavropol State Medical University, Russian Federation

ПАТОФИЗИОЛОГИЧЕСКИЕ МЕХАНИЗМЫ ЭКСПЕРИМЕНТАЛЬНОГО ОДОНТОГЕННОГО ВЕРХНЕЧЕЛЮСТНОГО СИНУСИТА

И. В. Кошель, Е. В. Щетинин, С. В. Сирак

Ставропольский государственный медицинский университет, Российская Федерация

This item offers a view on the outcomes of an experimental study involving an animal model, while the study was aimed at clarifying the clinical and morphological changes taking place in the maxillary tissues in case of odontogenic inflammation. The experiment was carried out on 30 guinea-pigs, where each of these had its right-side maxillary sinus as experimental, while the left side was observed as control. The simulated odontogenic infection focus in maxillary paradontium tissues was shown to cause purulent inflammation in the paranasal sinuses on the two sides, both in the intact and in the sensitized animals, while in the sensitized ones the pathology in the mucosa resulted in cyst-like formation development.

Key words: maxillary sinus, mucosa, odontogenic sinusitis

В статье представлены результаты экспериментального исследования на животных по уточнению характера клинко-морфологических изменений в тканях верхнечелюстного синуса при воспалительном процессе одонтогенной этиологии. Эксперименты проведены на 30 морских свинок, у каждой из которых правая верхнечелюстная пазуха являлась опытной, а левая использовалась в качестве контроля. Установлено, что экспериментально смоделированный очаг одонтогенной инфекции в тканях пародонта верхней челюсти вызывает гнойные воспалительные процессы в придаточных пазухах носа с обеих сторон как у интактных, так и у сенсibilизированных животных, причем у сенсibilизированных животных патологический процесс в слизистой оболочке приводит к формированию кистоподобных образований.

Ключевые слова: верхнечелюстной синус, слизистая оболочка, одонтогенный синусит