Reports. 2018;34:20-22. https://doi.org/10.1016/j.epsc.2018.04.017
11. Tsuman V. G., Mashkov A. E., Sigachev A. V. [et al.] Tactics of treating children with acute pancreatitis complicated by pancreatic fistulas and pseudocysts. *Rossiyskiy Vestnik detskoy khirurgii, anesteziologii i reanimatologi.* 2016;4(2):6-12.
12. Saad D. F., Gow K. W., Cabbabe S. Heissa K., Wulkana M. L. Laparoscopic cystogastrostomy for the treatment of pancreatic pseudocysts in children. *Journal of Pediatric Surgery.* 2005;40:13-17. https://doi.org/10.1016/j.jpedsurg.2005.07.041
13. Anadolulu A., Kafadar M. T., Gök M. A., Anadolulu Z. Laparoscopic spleen-preserving distal pancreatectomy with splenic vessel preservation for pancreatic pseudocyst in a 10-year-old boy. *Journal of Pediatric Surgery Case Reports*. 2018;34:10-12. https://doi.org/10.1016/j.epsc.2018.04.011

About authors:

Sokolov Yuriy Yur'evich, MD, PhD, Professor, Head of the Department of pediatric surgery; tel.: +9857743280; e-mail: sokolov-surg@yandex.ru

Efremenkov Artem Mikhaylovich, MD, Assistant of Professor of the Department of pediatric surgery; tel.: +79153001556; e-mail: efremart@yandex.ru

Tumanyan Grachik Tatevosovich, MD, PhD, Professor; +79032610790; e-mail: tymanyan@list.ru

Shapkina Anna Nikolaevna, MD, Associate Professor; tel.: +79147037589; e-mail: pedsurg2005@mail.ru

Akhmatov Roman Anatol'evich, MD, Resident of the Department of pediatric surgery; tel.: +79157327525; e-mail: romaahmatov@yandex.ru

Antonov Dmitriy Valer'evich, MD, PhD, Associate Professor; tel.: +79024729727; e-mail: podkb1@mail.ru

UDC 617.713-007.64
DOI – https://doi.org/10.14300/mnnc.2019.14138
ISSN – 2073-8137

REPLACING POLYMERIC CORNEAL RING SEGMENTS WITH ALLOGENIC BANDAGE IN PATIENT WITH PROGRESSING KERATOCONUS (A CLINICAL CASE STUDY)

Sheludchenko V. M. [1], Osipyan G. A. [1, 2], Youssef N. Yo. [1, 2], Khraystin Kh. [1], Dzhalili R. A. [1]

[1] Research Institute of Eye Diseases, Moscow, Russian Federation
[2] Center Vision Recovery, Moscow, Russian Federation

ЗАМЕНА РОГОВИЧНЫХ СЕГМЕНТОВ ИЗ ПОЛИМЕРНОГО МАТЕРИАЛА НА АЛЛОБАНДАЖ ПРИ ПРОГРЕССИРОВАНИИ КЕРАТОКОНУСА (КЛИНИЧЕСКОЕ НАБЛЮДЕНИЕ)

В. М. Шелудченко [1], Г. А. Осипян [1, 2], Н. Ю. Юсеф [1, 2], Х. Храйстин [1], Р. А. Джалили [1]

[1] Научно-исследовательский институт глазных болезней, Москва, Российская Федерация
[2] Центр восстановления зрения, Москва, Российская Федерация

Keratoconus is a serious problem for patients, which is accompanied by a decrease in visual functions and the progression of ectasia. The original bandage therapeutic-optical keratoplasty technique (intracorneal implantation of a wide allotransplant formed by femtolaser) allows long-term preservation of high visual function and management of keratectasia in a patient with keratoconus and corneal ectasia when routine methods (ICRS, cross-linking) are ineffective. Formation of the bandage led to improvement of visual function and cease of ectasia progression.

Keywords: keratoconus, bandage keratoplasty, implantation of intrastromal corneal ring segments, femtosecond laser, BTOK

Кератоконус является серьезной проблемой для пациента и сопровождается снижением зрительных функций с прогрессированием эктазии роговицы. В клиническом случае представлено применение метода бандажной лечебно-оптической кератопластики по собственной методике (интракорнеальная имплантация фемтосформированного широкого аллотрансплантата) у пациента с эктазией роговицы при кератоконусе и несостоятельности рутинных методов лечения. Данный подход позволил добиться длительного сохранения высоких зрительных функций и сдерживания кератоэктазии.

Ключевые слова: кератоконус, бандажная лечебно-оптическая кератопластика, имплантация интрастромальных роговичных сегментов, фемтосекундный лазер, операция «БЛОК»

For citation: Sheludchenko V. M., Osipyan G. A., Youssef N. Yo., Khraystin Kh., Dzhalili R. A. REPLACING POLYMERIC CORNEAL RING SEGMENTS WITH ALLOGENIC BANDAGE IN PATIENT WITH PROGRESSING KERATOCONUS (A CLINICAL CASE STUDY). *Medical News of North Caucasus*. 2019;14(3):550-553.
DOI – https://doi.org/10.14300/mnnc.2019.14138

Для цитирования: Шелудченко В. М., Осипян Г. А., Юсеф Н. Ю., Храйстин Х., Джалили Р. А. ЗАМЕНА РОГОВИЧНЫХ СЕГМЕНТОВ ИЗ ПОЛИМЕРНОГО МАТЕРИАЛА НА АЛЛОБАНДАЖ ПРИ ПРОГРЕССИРОВАНИИ КЕРАТОКОНУСА (КЛИНИЧЕСКОЕ НАБЛЮДЕНИЕ). *Медицинский вестник Северного Кавказа.* 2019;14(3):550-553.
DOI – https://doi.org/10.14300/mnnc.2019.14138

BTOK – bandage therapeutic-optical keratoplasty
ICRS – intrastromal corneal ring segments
UCVA – uncorrected visual acuity

Continuous scientific advancement in the field of ophthalmology, especially during the past 15–20 years, resulted in new possibilities for the treatment of keratoconus (the leading cause of keratectasia). Progressive by nature, the disease can have a significant impact on the visual functions and quality of life. Intrastromal keratoplasty, including the implantation of intrastromal corneal ring segments (ICRS), became a simplified technique of keratoconus treatment in recent years [1–4]. The surgery allows alteration of the curve of the anterior and posterior corneal surfaces, which can have a positive effect on its optical properties. However, most researchers agree that ICRS does not solve the problem of progressive keratoconus [5–8]. For instance, when the progression of corneal ectasia continues, it is usual practice to attempt to replace the existing segments by other segments, different characteristics, etc. In this regard, a group of researchers working at Research Institute of Eye Diseases (Moscow) suggested and then patented a new method of intrastromal keratoplasty – bandage therapeutic-optical keratoplasty (BTOK) (Russian patent 25655485-2014) [9, 10]. The surgery technique consists of the intrastromal implantation of a specially designed corneal allotransplant with original configuration that makes the area of thinning significantly thicker and improves optical properties of the cornea. The surgery effectively prevents the progression of ectasia and enhances visual acuity.

The present study describes a clinical case of replacing polymeric corneal ring segments with ones made of allogenic material in-patient with progressing keratoconus.

Clinical observation. Patient *M.*, born in 1978, Diagnosis: stage II keratoconus in the right eye; stage III keratoconus in the left eye, condition after implantation of corneal segments.

He sought medical treatment in the Research Institute of Eye Diseases (Moscow) in 2015. During the initial visit, the patient complained about deteriorating vision, periodic redness in the left eye that did not occur in the early postoperative period. The patient also told about having discomfort and parasitic optical phenomena when driving his car in the nighttime and looking at sources of light. The patient's history listed keratoconus diagnosed in 2009 and implantation of corneal rings in 2010. A retrospective analysis of patient's medical records helped make a detailed comparison of objective keratometric data and subjective patient's experience.

When enrolling in our medical facility, the patient underwent standard ophthalmological examination (biomicroscopy, visometry, refractometry and tonometry), as well as keratotopography (GALILEI-G6, Ziemer Ophthalmic Systems AG) before and after the surgery for evaluation of minimal corneal thickness and mean value of the refraction index in the central optical zone of 3 mm.

After considering patients complain and deterioration of vision in his left eye, which we regarded as decreasing effectiveness of the implanted corneal ring segments, we decided to remove the corneal ring segments as the first stage of the treatment plan, and after three months he had a second stage of punching BTOK.

Removal of corneal ring segments. The patient was placed under topical anesthesia; in the projection of the small technical «window» of the corneal layer, a diamond knife was used to perform a 1–1.5 mm radial cut on the cornea to the depth of the rigid element. Then, using a special round spatula with a hook-shaped working tip, a segment was hooked through that small «window» and pulled out from the stroma. The corneal surface and intrastromal pocket were then treated with an antimicrobial agent.

No complications occurred during the surgery and early postoperative period. Instillations of an antimicrobial drug were prescribed for seven days after the surgery, as well as a nonsteroidal drug for two weeks and artificial tear installations for 1–2 months. Two weeks after the surgery, a significant decrease of uncorrected visual acuity (UCVA) was observed with values similar to retrospective data and lasted three months. In the same manner, the corneal index of refraction has increased, while minimal pachymetry values have moderately decreased when compared with retrospective data.

Analysis of the first stage of the intervention showed that from 2010 to 2015, keratoconus has progressed in the left eye accompanied by increased ectasia (Fig. 1).

The second stage of the treatment plan (BTOK surgery) was performed three weeks after ICRS removal.

BTOK surgery technique. Looking at corneal topogram, a proposed layout and size of the future «band-shaped» transplant.

Femtosecond laser (AMO Intralase FS60, USA) was used to cut a donor cornea, preserved in the Borzenok-Moroz solution, into a layered «band-shaped» transplant constituting a 320 μm thick open ring (resembling Landolt ring); the femtosecond laser was following the predetermined algorithm to cut the cornea to the depth of 290 μm and form a circular lamellar pocket.

BTOK surgery and cutting of the donor cornea were performed using femtolaser parameters optimized for safety with 1.5 μJ pulse energy, 5.5 μm distance between the spots, 6.5 μm distance between the concentric circles of the spiral pattern, and 3.0 μm spot diameter.

The sector of keratectasia was marked on the patient's cornea with consideration of the area of keratectasia seen on his keratotopogram. The transplant was inserted into the intralamellar pocket of the patient's cornea through a small radial cut in the pocket's anterior wall. The transplant was then arranged in the projection of ectasia to correspond to the prepared markings.

During the post-operative period, the patient used instillations of a combined drug (antimicrobial and glucocorticoid), and nonsteroidal anti-inflammatory drugs. The patient was discharged from the facility on the fifth day after the surgery (Fig. 2).

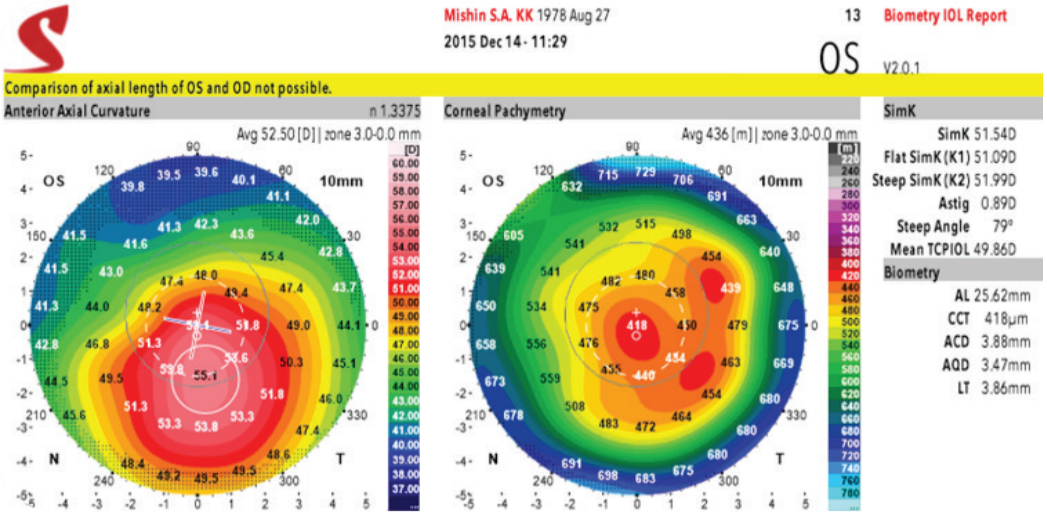

Fig. 1. Keratotopogram of the left eye after ICRS removal. The steepening of the central ectasia zone has shown

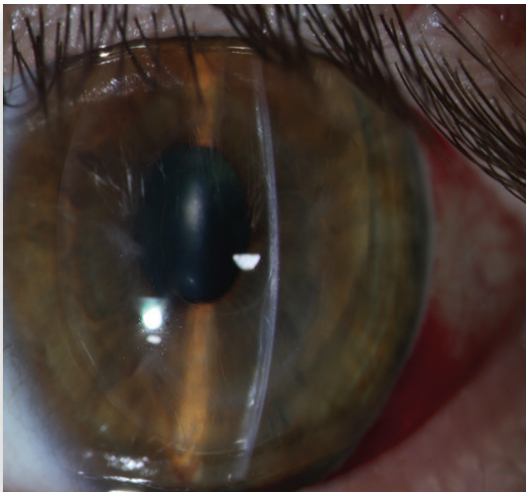

Fig. 2. Photo of the patient's left eye five days after BTOK surgery. The cornea is an areactive, semitransparent optical section

Dynamic observation revealed that 30 months after BTOK patient's visual acuity on the left eye was 0.66 (20/30). According to keratotopography data, mean corneal refraction in the 3 mm optical zone was 44.3 Diopters, and minimal pachymetry – 411 µm (Fig. 3). Comparative analysis of keratometric and functional data of the patient after ICRS implantation, as well as 6, 12, 24, and 30 months after BTOK proved that mean refraction in the central zone of the cornea after BTOK remained stable compared with values after ICRS implantation. Visual acuity was also higher after BTOK and stable during the whole postoperative period.

Conclusions. The most common method of ICRS implantation in patients with progressing keratoconus has initially paid off because it improved optical parameters of the cornea resulting in lower astigmatism and higher visual acuity. However, the hopes of stabilizing ectasia with that procedure did not realize, and so corneal cross-linking was performed. Some patients with ICRS lose the initial effect after several years and require a second surgery. The presented clinical case demonstrates that BTOK surgery can be performed successfully in such patients to improve optical parameters of the cornea and increase visual resolution, as well as provide required stabilization. Progression of ectasia can be halted thanks to the intrastromal transplant of significant surface area being carefully placed in the most sensitive ectasia zone, which is the main difference between BTOK and ICRS implantation. Most importantly, the patient receives a lasting quality of live improvement.

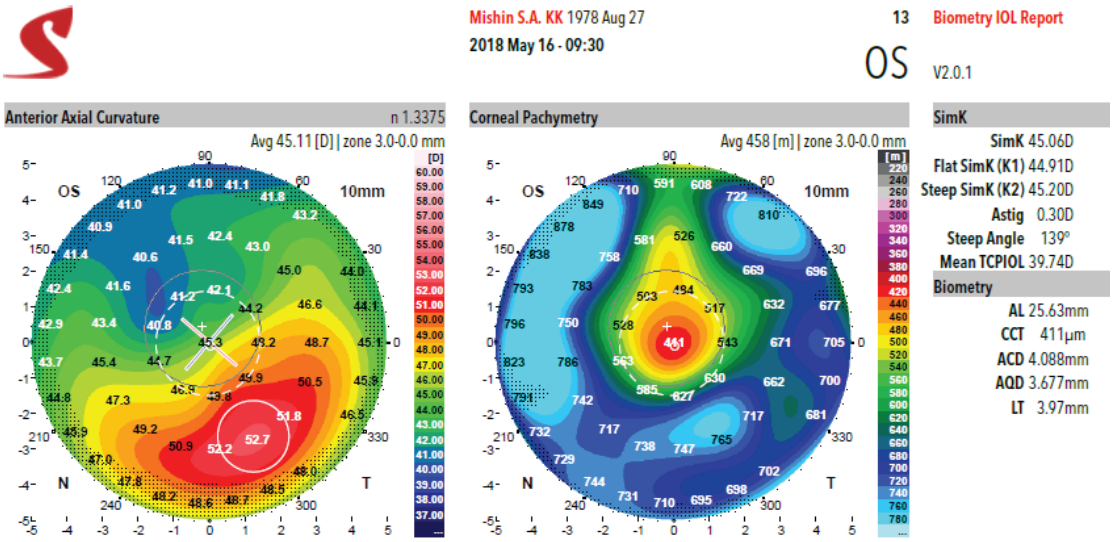

Fig. 3. Keratotopogram of patient's left eye 2.5 years after BTOK surgery. The thickening of the central optical area of the cornea has shown

Disclosures:
The authors declare no conflict of interest.

References

1. Avetisov S. E., Karamyan A. A., Yusef Yu. N., Egorova G. B., Mahmoud M. I. [et al.] Implantation of intrastromalny corneal segments at a keratoconus. *Annals of ophthalmology*. 2012;128(6):20-24.
2. Colin J. Intacs inserts for treating keratoconus: one-year results. *Ophthalmology*. 2011;108(8):1409-1414. https://doi.org/10.1016/S0161-6420(01)00646-7
3. Alio J. L. One or 2 intacs segments for the correction of keratoconus. *J. Cataract. Refract. Surg.* 2005;31(5):943953. https://doi.org/10.1016/j.jcrs.2004.09.050
4. Alio J. L. Intracorneal asymmetrical rings for keratoconus: implant where should the thicker segment. *J. Refract. Surg*. 2006;22(3):307-309. https://doi.org/0.3928/1081-597X-20060301-19
5. Cosar C. B., Sridhar M. S., Sener B. Late onset of deep corneal vascularization: a rare complication of intrastromal corneal ring segments for keratoconus. *Eur. J. Ophthalmol*. 2009;2:298-300. https://doi.org/10.1177/112067210901900222
6. Ibáñez-Alperte J., Pérez-García D., Cristóbal J. A., Mateo A. J., Río B. J. [et al.] Keratitis after Implantation of Intrastromal Corneal Rings with Spontaneous Extrusion of the Segment. Case Report. *Ophthalmol.* 2010;2:42-46. https://doi.org/10.1159/000320585
7. Kymiomis G. D. Long-term follow-up of Intacs in keratoconus. *Am. J. Ophthalmol*. 2007;143:236-244. https://doi.org/10.1016/j.ajo.2006.10.041
8. Martin R. G. Wedge resection in the cone after failed refractive surgery in patient with keratoconus. *J. Refract. Surg*. 1995;21(3):348-350.195. https://doi.org/10.1016/S0886-3350(13)80145-9
9. Mamikonyan V. R., Avetisov S. E., Osipyan G. A., Egorova G. B., Doguzov V. A. [et al.] Intralamellar bandage keratoplasty for the treatment of progressive keratoconus (draft report). *Annals of ophthalmology*. 2015;131(1):18-23. https://doi.org/10.17116/oftalma2015131118-23
10. Mamikonyan V. R., Osipyan G. A., Khraystin Kh., Karamyan A. A., Rozinova V. N. Bandage therapeutic-optical keratoplasty in case of pellucid marginal corneal degeneration. *Point of View. East-West*. 2018;1:18-21. https://doi.org/10.25276/2410-1257-2018-1-18-21

About authors:

Sheludchenko Vyacheslav Mikhailovich, DMSc, Professor, Chief Researcher at the Department of corneal and optic nerve pathology; tel.: +79161747208; e-mail: scotoma@mail.ru

Osipyan Grigoriy Albertovich, CMSc, Senior Researcher at the Department of corneal and optic nerve pathology; tel.: +79031499544; e-mail: gregor79@yandex.ru

Youssef Naim Youssef, DMSc, Professor, Vice-Principal for Innovations; tel.: +74995179900; e-mail: info@cvz.ru

Khraystin Khusam, postgraduate student; tel.: +79998250479; e-mail: khrestin89@mail.ru

Dzhalili Rubaba Ali Kyzy, resident medical practitioner; tel.:+79851747771, e-mail: rubgam@mail.ru

UDC 616-089-053.2
DOI – https://doi.org/10.14300/mnnc.2019.14139
ISSN – 2073-8137

GOSSYPIBOMA OF THE RIGHT HEMITHORAX IN CHILD

Bataev S. M. [1, 2], Ignatyev R. O. [1, 2], Romashin M. A. [1], Zurbaev N. T. [1, 2], Eremin D. B. [2], Bataev A. S. [1]

[1] Pirogov Russian National Research Medical University, Moscow, Russian Federation
[2] Speranskiy Children's Municipal Hospital № 9, Moscow, Russian Federation

ГОССИПИБОМА ПРАВОГО ГЕМИТОРАКСА У РЕБЕНКА

С. М. Батаев [1, 2], Р. О. Игнатьев [1, 2], М. А. Ромашин [1], Н. Т. Зурбаев [1, 2], Д. Б. Еремин [2], А. С. Батаев [1]

[1] Российский национальный исследовательский медицинский университет им. Н. И. Пирогова, Москва, Российская Федерация
[2] Детская городская клиническая больница № 9 им. Г. Н. Сперанского, Москва, Российская Федерация

Gossypiboma is a rare complication of surgical interventions that can have severe medical and legal consequences. We report the clinical case of a boy who was 4 years old and was operated on at 1.5 months old for atrial septal defect and partial abnormal drainage of the right pulmonary veins into the right atrium. After 3 years, a mass was found in the projection of the basal segments of the right lung. An X-ray showed signs of calcification. Thoracoscopy was performed followed by conversion to open surgery and removal of the gossypiboma with a fibrous capsule of 3×3.5×3 cm. An examination 6 months after surgery showed no complaints, and growth and development were normal according to age. The diagnosis of gossypiboma should be included when determining a diagnosis in all cases where there is a history of surgery and non-specific clinical and diagnostic manifestations.

Keywords: gossypiboma, pleural cavity, cardiac surgery, children

Госсипибома является достаточно редким осложнением после хирургического вмешательства, которое может иметь серьезные медицинские и правовые последствия. Приводится клинический случай у ребенка, 4 лет, который был оперирован в возрасте 1,5 месяцев по поводу дефекта межпредсердной перегородки и частичного аномального дренажа пра-